
Batch Name: 72046

Batch Creator: SWORD 1

Batch Creation Date: 9/21/2005

Batch Creation Time: 11:40:25

Number of Pages: 10 [All]

Printed by: SWORD 1

Print Date: 9/21/2005

Print Time: 11:45:22

From fill@www.libraries.wright.edu Tue Sep 20 15:21:27 2005
Return-Path: <fill@www.libraries.wright.edu>
Received: from mulnx12.mcs.muohio.edu (mulnx12.mcs.muohio.edu [134.53.6.67])
by sigerson.sword.org (8.13.4/8.13.4/Debian-3) with ESMTTP id j8KJLRw6009255
for <requests@sword.org>; Tue, 20 Sep 2005 15:21:27 -0400
Received: from mulnx24.mcs.muohio.edu (mulnx24.mcs.muohio.edu [134.53.6.11])
by mulnx12.mcs.muohio.edu (Switch-3.1.6/Switch-3.1.6) with ESMTTP id j8KJKxUB026417
for <requests@sword.org>; Tue, 20 Sep 2005 15:20:59 -0400
Received: from sms1.wright.edu (sms1.wright.edu [130.108.66.31])
by mulnx24.mcs.muohio.edu (Switch-3.1.6/Switch-3.1.6) with ESMTTP id j8KJKwuK004059
for <requests@sword.org>; Tue, 20 Sep 2005 15:20:59 -0400
Received: from conversion-daemon.sms1.wright.edu by sms1.wright.edu
(iPlanet Messaging Server 5.2 HotFix 2.04 (built Feb 8 2005))
id <0IN400K01R26VZ@sms1.wright.edu>
(original mail from fill@www.libraries.wright.edu)
for requests@sword.org; Tue, 20 Sep 2005 15:20:58 -0400 (EDT)
Received: from staff150 ([130.108.169.150])
by sms1.wright.edu (iPlanet Messaging Server 5.2 HotFix 2.04 (built Feb 8
2005)) with ESMTTP id <0IN400ARJR2Y0V@sms1.wright.edu> for requests@sword.org;
Tue, 20 Sep 2005 15:20:58 -0400 (EDT)
Date: Tue, 20 Sep 2005 19:20:59 +0000 (GMT)
From: Fordham Interlibrary Loan <fill@www.libraries.wright.edu>
Subject: Please fill request
To: requests@sword.org
Message-id: <0IN400K59R2YVZ@sms1.wright.edu>
Content-transfer-encoding: 7BIT
X-Real-ConnectIP: 130.108.66.31
X-Scanned-By: MIMEDefang 2.45
X-Scanned-By: MIMEDefang 2.52 on 134.53.6.11

This request has been forwarded from ILL by barb.

Please fill this request for FORDHAM HEALTH SCIENCES LIBRARY

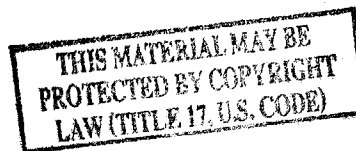72046

Call Number: 81259041104

Journal Title: american journal of obstetrics and gyn
Journal Vol: 41
Journal Issue:
Journal Year: 1941
Article Title: A clinical study of estrogen therapy pellet implantation
Article Author: Mishell D
Article Pages: 1009-1017

Customer Information:

Name: Glaser, Rebecca
Status: Faculty
Address: SOUTHVIEW (via Kettering Hosp),
Site:
E-Mail Address: rglaser@woh.rr.com
Phone: 937-885-4555
Department: School of Medicine



72046

9 pgs. scanned
9/21/05

- Miescher, K., Wettstein, A., and Tschopp, E.: *Biochem. J.* 30: 1970, 1936. (49)
 Nathanson, I. T., Franseen, C. C., and Sweeney, A. R., Jr.: *Proc. Soc. Exper. Biol. & Med.* 39: 385, 1938. (50) Nelson, W. O., and Gallagher, T. F.: *Science* 84: 230, 1936. (51) Nelson, W. O., and Merkel, C. G.: *Proc. Soc. Exper. Biol. & Med.* 36: 823, 1937. (52) Nelson, W. O., and Gallagher, T. F.: *Anat. Rec.* 64: 129, 1935. (53) Noble, R. L.: *J. Endocrinol. (London)* 1: 184, 1939. (54) Papanicolaou, G. N.: *Am. J. Anat.* 52: 519, 1933. (55) Papanicolaou, G. N., Ripley, H. S., and Shorr, E.: *Endocrinology* 24: 339, 1939. (56) *Idem*: *Proc. Soc. Exper. Biol. & Med.* 37: 689, 1938. (57) Robson, J. M.: *Ibid.* 35: 49, 1936. (58) Ruzicka, L., Goldberg, M. W., and Rosenberg, H. R.: *Helv. chim. Acta.* 18: 1487, 1935. (59) Ruzicka, L., Hofmann, K., and Meldahl, H. F.: *Ibid.* 21: 372, 1938. (60) Salmon, U. J.: *Proc. Soc. Exper. Biol. & Med.* 38: 352, 1938. (61) *Idem*: *Endocrinology* 23: 779, 1938. (62) *Idem*: *Proc. Soc. Exper. Biol. & Med.* 37: 488, 1937. (63) Salmon, U. J., Geist, S. H., and Walter, R. I.: *AM. J. OBST. & GYNEC.* 38: 264, 1939. (64) Salmon, U. J., Walter, R. I., and Geist, S. H.: *Proc. Soc. Exper. Biol. & Med.* 39: 467, 1938. (65) Salmon, U. J., and Frank, E. T.: *Ibid.* 33: 612, 1936. (66) Salmon, U. J., and Geist, S. H.: *Ibid.* 40: 252, 1939. (68) Salmon, U. J., and Geist, S. H.: *Ibid.* 40: 522, 1940. (69) Salmon, U. J., and Geist, S. H.: *J. Clin. Investigation*. In Press. (70) Starkey, W. F., and Leatham, J. H.: *Proc. Soc. Exper. Biol. & Med.* 39: 218, 1938. (71) Sturgis, W. C., Abarbanel, A. K., and Nader, D. S.: *AM. J. OBST. & GYNEC.* 39: 102, 1940. (72) Wolfe, J. M., and Hamilton, J. B.: *Proc. Soc. Exper. Biol. & Med.* 37: 189, 1937. (73) *Idem*: *Endocrinology* 21: 603, 1937. (74) Zondek, B., and Rozin, S.: *Lancet* 1: 504, 1939. (75) Zondek, B., and Rozin, S.: *J. Obst. & Gynaec. Brit. Emp.* 45: 919, 1939. (76) Zuckerman, S.: *Lancet* 2: 676, 1937.

A CLINICAL STUDY OF ESTROGENIC THERAPY WITH PELLET IMPLANTATION

DANIEL R. MISHELL, M.D., NEWARK, N. J.

(From the Clinic of the Woman's Hospital of the State of New York)

THE value of estrogenic substitution therapy in the treatment of menopausal disorders is now well established. Heretofore, this has been accomplished by means of intramuscular injection, oral administration, and local application. In 1937, Deanesly and Parkes¹ studied a new method of administration of the hormone. They implanted subcutaneously highly compressed tablets of crystalline estrone in laboratory animals. They believed that by this method a continuous supply of the hormone could be released in the body, thus simulating the normal physiologic mechanism. They observed that the prolonged action was associated with increased effectiveness of the hormone per unit weight which was perhaps explained by more complete utilization (decreased waste). A year later the same authors² in another series of animal experiments studied the absorption rate of the implanted tablets and determined the quantity of hormone used per month by reweighing the implanted tablets at the termination of the experiment. The effects of this long-continued action were in most respects similar to those described by other authors as resulting from the repeated injections of estrogens and the resulting inhibition of formation of the gonadotropic and growth-promoting hormones of the anterior pituitary. As a result of these animal experiments, they suggested that the method would be useful in the treatment of conditions requiring a long-continued and uninterrupted estrogenic effect.

Clinicians began to apply this new mode of therapy to the treatment of the menopausal syndrome. P. M. Bishop³ found that the implantation of 14 mg. of estrone in the abdominal wall in a menopausal woman caused a marked decrease in the number of hot flushes within a period of one week; an effect maintained for approximately a month. The calculated daily absorption was 0.5 mg. or 5000 I.U.

Salmon, Water, and Geist⁴ described a technique of implantation in the gluteal region, and noted complete relief with substitution therapy of 4 to 7 mg. of crystalline estradiol benzoate. They concluded that 25 to 50 mg. should maintain a patient symptom free for many months and suggested that it be given prophylactically to patients following x-ray or surgical castration. MacBryde and others⁵ implanted 100 mg. of stilbestrol pellets in the lumbar region and were able to show endometrial proliferation in seven days.

Bennet, Biskind, and Marks⁶ reported a series of 21 menopausal patients who received compressed tablets of theelin. These pellets, 3 to 10 in number, weighing 5 to 16 mg., were loaded in a hollow 12-gauge needle and implanted by pressure with a stylet. Biopsies of the vaginal mucosa showed increased proliferation two weeks after treatment. All patients improved under treatment. Symptoms returned gradually and were relieved by second implantation. They noted no infection, inflammation, or abnormal uterine bleeding.

During the past year we have studied the effects of implantation of a single pellet of crystalline estrogens 45 to 65 mg. in weight, in a series of 28 cases. The technique employed was simple and is briefly described as follows: The site chosen for implantation was the region of the groin just above Poupart's ligament. Under $\frac{1}{2}$ per cent novocaine anesthesia, a small incision was made in the skin to allow the introduction of a small curved hemostatic forceps. A channel was made in the subcutaneous tissue and the hemostat withdrawn. The pellet was then introduced a few centimeters laterally to the line of the incised wound. The edges of the incision were then strapped together with sterile adhesive. No sutures were ever used. The patients did not complain of any adverse symptoms and the area healed by primary union within forty-eight hours. The procedure was simple and took but a few seconds longer than an intramuscular injection.

The cases chosen for this study were for the most part those with well-defined symptoms associated with the menopause. These, in turn, were subdivided into the following groups: namely, surgical and irradiation castration, and spontaneous menopause. The common symptoms of menopause, such as hot flushes, sweats, headaches, joint pains, nervousness, irritability, pruritus vulvae, and dyspareunia, were noted at the time of implantation. Vaginal smears, and in some instances, endometrial biopsies were taken during the period of observation. It was found that a week or ten days elapsed in most of the cases before any relief was noted by the patient. In no instance did any abnormal bleeding occur. No evidence of infection, inflammation, or foreign body reaction was observed.

A group of patients with primary amenorrhea were treated by implantation with estrogen pellets. The effect upon development of the secondary sex characteristics and growth in the size of the uterus were noted. It was found that in patients with complete lack of breast de-

velopment, a remarkable increase in size of both the nipple and mammary gland was observed in a comparatively short period of time, i.e., five to six weeks.

Several patients with secondary amenorrhea of long standing were treated with estrogen pellets, and the effect upon the menstrual cycle and the size of the uterus were noted. In this group, the patients did not experience any change in their symptoms unless the secondary amenorrhea was associated with signs of early menopause. The cases are briefly described as follows:

GROUP I. SURGICAL AND IRRADIATION MENOPAUSE

C. R., aged 32 years, had a panhysterectomy in 1939. She had hot flushes, 10 to 15 daily, severe headaches, nervous irritability, and loss of appetite. *Previous therapy*: estrone 20,000 I.U. every week for two months. There was moderate improvement. *Implant*: June 22, 1940, 56 mg. estrogen. *Smears*: June 22, typical castrate smear. September 14, good estrogenic function. October 19, fair estrogenic function.

Result.—All symptoms disappeared up to Oct. 19, 1940, at which time headaches returned. Complete relief four months.

M. K., aged 40 years, had a hysterectomy in 1938. She had hot flushes and severe itching and burning of vulva and vagina. *Previous therapy*: estrone 10,000 I.U. twice a week at intervals for one year with relief of flushes, but not of pruritus. Estrogenic ointment for six months with relief of burning and itching. *Implant*: Aug. 19, 1940, 63.5 mg. estrogen. *Smears*: Mar. 7, 1940, slight function; Sept. 26, 1940, good estrogenic function.

Result.—Relief of all symptoms to date, four months after implantation. No evidence of pruritus vulvae.

Y. S., aged 40 years, had a hysterectomy in 1937. Hot flushes occurred 6 to 8 times daily. Severe headaches. *Previous therapy*: Estrone 10,000 I.U. twice a week for one year. Moderate relief of flushes. *Implant*: Feb. 27, 1940, 60 mg. estrogen. *Smears*: Feb. 14, 1940, marked decrease estrogenic function; March 12, 1940, good estrogenic function.

Result.—Relief of all flushes. Persistence of headaches. Referred for allergy study after two months' observation.

E. Z., aged 43 years, had a hysterectomy in 1937. Hot flushes occurred 10 to 15 times daily. Severe pruritus vulvae. *Previous therapy*: Estrone 10,000 I.U. once or twice a week from June 29, 1940, to Sept. 7, 1940. Flushes reduced, 2 daily. Pruritus unaffected. *Implant*: Sept. 7, 1940, 53.5 mg. estrogen.

Result.—Complete relief of all symptoms two weeks after implant. Oct. 19, 1940, patient in excellent condition. No flushes or pruritus. Last observed on Dec. 21, 1940, condition excellent.

E. B., aged 40 years, had a bilateral oophorectomy in 1930. Pruritus vulvae. Flushes occurred 6 to 8 times daily. Examination, atrophic vaginitis. *Previous therapy*: Estrone 10,000 I.U. once or twice a week at intervals. Relief of flushes but not of pruritus. *Implant*: June 1, 1940, 64 mg. estrogen.

Result.—Sept. 21, 1940, no flushes. Itching disappeared. Mucous membrane healthy. Oct. 5, 1940, occasional itching and few flushes. Complete relief after four months' treatment.

F. G., aged 42 years, had a hysterectomy in 1930. Hot flushes occurred 10 to 15 times daily. Emotional disturbance. *Previous therapy*: Estrone 10,000 I.U. twice a week from Dec. 30, 1939, to May 1, 1940. Symptoms returned when treatment was stopped. *Implant*: May 1, 1940, 68.8 mg. estrogen. *Smears*: May 1, 1940, 10 per cent function; July 7, 1940, 90 per cent function.

Result.—Complete relief after five and one-half months after implantation. Re-implantation on Nov. 2, 1940, of 62.5 mg. of estrogen.

F. M., aged 28 years, had a panhysterectomy in 1939. Hot flushes occurred 15 to 30 times daily. Psychoneurosis. She was confined in Bellevue Psychopathic Hospital for two weeks. *Previous therapy*: Estrone 10,000 I.U. three times a week. Not satisfactory. *Implant*: April 6, 1940, 52 mg. estrogen.

Result.—One week after implant the flushes were absent. There was relief of all symptoms until Sept. 15, 1940. Return of libido and emotional stability. Gain in weight. Reimplantation on Oct. 5, 1940, of 50 mg. estrogen. On Dec. 14, 1940, she felt and looked well. There have been no flushes or emotional upset.

A. C., aged 53 years, had a hysterectomy in 1936. Hot flushes occurred 8 to 10 times daily. She had pruritus vulvae, nervousness, insomnia, and crying spells. *Previous therapy*: Estrone 10,000 I.U. twice a week for one year. Relief of symptoms. Recurrence after injections were stopped. *Implant*: Aug. 29, 1940, 56 mg. estrogen. *Smears*: Aug. 29, 1940, typical castration smear; Sept. 26, 1940, good estrogenic function.

Result.—Sept. 26, 1940, no flushes, itching, or burning. More energy. Still under observation.

M. B., aged 39 years, had irradiation in 1939 for menorrhagia. Hot flushes occurred 20 to 30 times daily. Severe headaches. *Previous therapy*: Estrone 30,000 to 40,000 I. U. twice a week for six months. No relief. *Implant*: April 6, 1940, 55 mg. estrogen. *Smears*: April 6, 1940, typical castration cells; May 5, 1940, moderate function. *Biopsy*: May 5, 1940, complete atrophy of endometrium.

Result.—May 5, 1940, flushes now 10 daily. Patient did not return for further observation or therapy. Partial improvement, no effect upon endometrium.

M. C., aged 42 years, had postradiation in 1937 for fibromyoma. Severe hot flushes occurred 5 to 10 times daily. Nervousness, irritability, insomnia, dyspareunia were present. *Previous therapy*: Estrone 10,000 I.U. once or twice a week for two years. Moderate but transient relief. *Implant*: June 15, 1940, 50 mg. of estrogen. *Smears*: June 17, 1940, decreased estrogenic function; July 8, 1940, excellent estrogenic function; Sept. 23, 1940, decreased function.

Result.—Complete relief of all symptoms for three months. After September 15, she noticed recurrence of flushes. Reimplanted Sept. 28, 1940, 57 mg. of estrogen. Complete relief of all symptoms when last seen, Dec. 23, 1940.

GROUP II. SPONTANEOUS MENOPAUSE

A. N., aged 40 years, had a spontaneous menopause 1 year previously. Hot flushes occurred from 15 to 20 times daily. She was nervous and had lost weight (18 pounds). *Previous therapy*: 10,000 to 20,000 I.U. estrone per week sporadically with moderate relief. Flushes occurred 5 or 6 times a day. *Implant*: April 18, 1940, 50 mg. of estrogen. *Smears*: April 1, 1940, typical castration smear; Sept. 12, 1940, good estrogenic function.

Result.—Complete relief two weeks following implantation. Duration, 5 months. Reimplantation on Sept. 26, 1940, of 58.5 mg. of estrogen following return of symptoms. Still under observation.

K. L., aged 50 years, had a spontaneous menopause complicated with thyrotoxicosis and hypertension. Blood pressure 230/110 (June 1, 1940). Vertigo, tinnitus, vomiting, hot flushes were present. *Previous therapy*: Thyroidectomy four months before. No estrogenic therapy. *Implant*: June 1, 1940, 57 mg. of estrogen. *Smears*: June 1, 1940, slight estrogenic function; July 2, 1940, excellent estrogenic function; Sept. 2, 1940, good estrogenic function; Sept. 20, 1940, decreased estrogenic function. Basal metabolic rate plus 22 per cent. Blood cholesterol 107 mg. per 100 c.c. of plasma (June 3, 1940).

Result.—Two weeks following implant, symptoms improved. No vertigo, vomiting, or tinnitus. Blood pressure 200/110, on Sept. 26, 1940. Return of symptoms five months later. Reimplantation of 59.5 mg. of estrogen Nov. 7, 1940. Has been able to do all housework and is symptom free up to present time, Dec. 23, 1940.

W. J., aged 48 years, had spontaneous menopause 3 years ago. Hot flushes 6 to 10 times daily. She was nervous, irritable, and had pruritus. *Previous therapy*:

Estrone 10,000 I.U. once or twice a week, and for 2 years had relief from flushes. *Implant*: May 6, 1940, 52 mg. of estrogen. *Smears*: March 18, typical castration cells; June 23, excellent estrogenic function; September 5, good estrogenic function; October 1, return of castration cells.

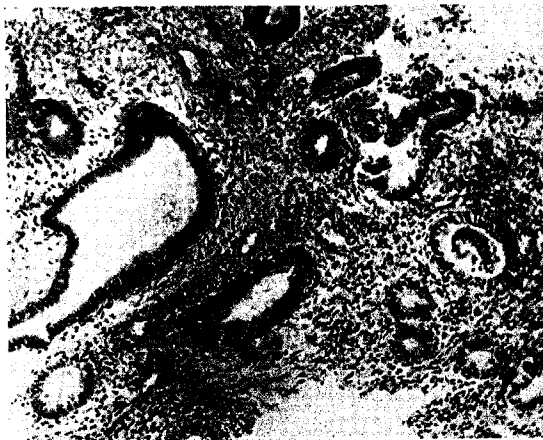

Fig. 1.—Endometrial biopsy before therapy; nonfunctioning endometrium cystic glands. Dense stroma.

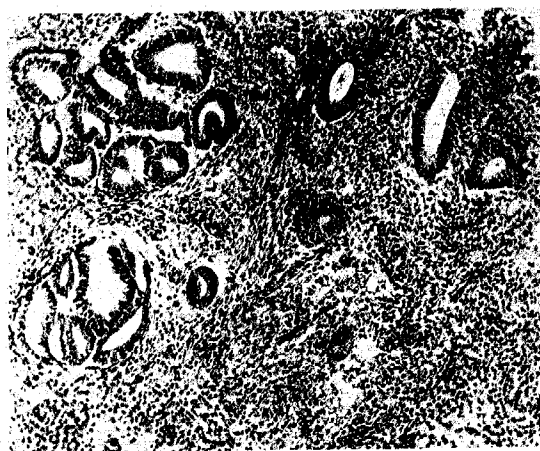


Fig. 2.—Seven weeks after implantation of 55 mg. of estronic pellet. Moderate proliferation of endometrial glands, showing effect of mild estrogenic activity.

Result.—Two weeks after implantation, complete absence of flushes. General feeling of well-being. Duration, four and one-half months. Reimplantation on Oct. 1, 1940, of 56 mg. of estrogen, with alleviation of symptoms one week later. Still under observation.

P. H., aged 53 years, had a spontaneous menopause since June, 1939. Hot flushes occurred 2 to 4 times daily. Nervousness, insomnia, and irritability were present. She had had no previous therapy. *Implant*: April 18, 1940, 50 mg. of estrogen. *Smears*: April 18, marked decrease of ovarian function; May 19, excellent estrogenic function; October 5, decreased function.

Result.—No flushes. General condition much improved for period of six months. Return of symptoms October, 1940. Reimplantation on October 10 of 57.5 mg. of estrogen. Still under observation. Symptom free to date, Dec. 24, 1940.

M. R., aged 35 years, had menopause precoc. Her last menstrual period occurred in December, 1935. Hot flushes occurred 3 to 4 times daily. There were malaise and absence of libido. *Previous therapy:* Sporadic treatment with injections of estrone for two years. No effect on general condition. *Implant:* Aug. 15, 1940, 55 mg. of estrogen. *Smears:* August 15, typical castration cells; September 26, very good estrogenic function. *Biopsy:* Oct. 11, 1938, atrophic endometrium (Fig. 1). Oct. 3 and 17, 1940, proliferative endometrium (Fig. 2).

Result.—All symptoms were relieved three weeks after implantation. No flushes, return of libido. She was able to do all housework. Three months later, reappearance of symptoms, followed by reimplantation of 60 mg. of estrogen on Nov. 18, 1940. Still under observation.

A. G., aged 47 years, had decreased menstrual periods for two years. She also had severe hot flushes, twitching of eyelids, insomnia, and nervousness. *Previous therapy:* Estrone 10,000 I.U. twice a week. Moderate but transient relief. *Implant:* Aug. 19, 1940, 56.5 mg. of estrogen. *Smears:* October 7, fair estrogenic function.

Result.—Flushes completely disappeared one week after implant. She sleeps better, and is not so nervous. Still under observation four months after implantation.

E. C., aged 45 years, had had scant periods for two years. She also had headaches, hot flushes, 4 to 5 times daily, lack of libido, and was always tired. There had been no previous therapy. *Implant:* Aug. 31, 1940, 46 mg. of estrogen. *Smears:* August 31, poor estrogenic function; September 19, excellent estrogenic function; October 3, excellent estrogenic function.

Result.—Oct. 3, 1940, feels well. There are no flushes or headaches, and she has more energy. There is marked improvement clinically. Still under observation four months after implantation.

D. D., aged 31 years, had menopause precoc. She had had irregular periods for one year, every two to three months with one-hour flow. There were severe headaches, hot flushes, and absence of libido. There had been no previous therapy. *Implant:* May 4, 1940, 45 mg. of estrogen. *Smears:* May 4, no estrogenic function; May 18, fair estrogenic function; September 21, decreased function. *Biopsy:* September 21, abortive secretory phase.

Result.—June 15, increased sense of well-being. No flushes or headaches were present. Relief of symptoms for five months.

R. T., aged 27 years, had menopause precoc. Hot flushes occurred 20 times daily. She had had amenorrhea for three years. *Previous therapy:* Substitution therapy 10,000 I.U., three times a week, thyroid. *Implant:* Aug. 28, 1940, 38.5 mg. of estrogen. *Biopsy:* Feb. 17, 1940, extreme atrophy.

Result.—Flushes were slight, 2 to 4 times daily, one month after implant. Libido increased. There was relief of symptoms for three months. Flushes reappeared Nov. 23, 1940, but not as severe as before. Reimplantation of 47 mg. of estrogen on November 23.

L. D., aged 32 years, had pruritus vulvae, dyspareunia, atrophy of vulva, and leucoplakia of vulva. *Previous therapy:* Estrogenic ointment for one year at intervals. Moderate relief while under therapy. *Implant:* June 1, 1940, 46.5 mg. of estrogen. *Biopsy:* October 1, nonfunctioning endometrium. *Vaginal biopsy:* parakeratosis.

Result.—Complete relief of all symptoms for four months. Return of itching and soreness Oct. 1, 1940. Leucoplakia of buccal mucous membrane 1 cm. in area anterior to Stenson's duct noticed on Oct. 26, 1940. Itching was worse. Reimplantation of 53.5 mg. of estrogen on Dec. 7, 1940.

GROUP III. PRIMARY AND SECONDARY AMENORRHEA

B. P., aged 23 years, had primary amenorrhea, absence of breast development and pubic hair. There had been no previous therapy. *Implant:* Dec. 5, 1939, 75 mg. of estrogen. *Smears:* December 5, no function; Jan. 15, 1940, excellent function.

Result.—There was noticeable development of both breasts within eight weeks, slight growth of pubic hair, but no menstrual period occurred.

F. S., aged 20 years, had primary amenorrhea. Hypertrichosis. *Previous therapy:* X-ray stimulation of pituitary. Substitution therapy. Infantile uterus on examination. *Implant:* April 6, 1940, 50 mg. of estrogen; Aug. 21, 1940, 57 mg. of estrogen.

Result.—Uterus was slightly larger. There was spotting from September 14 to 17. First real period occurred on October 29 to November 4. Breasts are larger, and the patient feels well.

E. J., aged 30 years, had primary amenorrhea. Hot flushes occurred 6 to 8 times daily. She had dyspareunia, and no breast development. *Previous therapy:* Substitution therapy 10,000 I.U., three times a week. *Implant:* April 28, 1940, 48 mg. of estrogen.

Result.—There had been no flushes six months after pellet implantation. Dyspareunia improved. Patient felt much better with implantation than with injections. Reimplantation of 59 mg. of estrogen Oct. 17, 1940, following return of flushes. Breasts were noticeably larger within eight weeks after implantation, but became smaller four months later.

A. W., aged 29 years, had secondary amenorrhea. Last menstrual period occurred May, 1940. Periods were at prolonged intervals of 6 months. *Examination:* Hypoplasia of uterus. No previous therapy. *Implant:* Aug. 18, 1940, 58 mg. of estrogen. *Biopsy:* September 26 nonfunctioning endometrium.

Result.—Failure. Patient was referred for x-ray therapy to pituitary. (Stimulation.)

B. M., aged 32 years, had secondary amenorrhea. There had been amenorrhea for one year. No previous therapy. No menopausal symptoms. *Implant:* Feb. 24, 1940, 50 mg. of estrogen; Aug. 14, 1940, 51.5 mg. of estrogen. *Smears:* February 24, no function; March 30, excellent function; April 13, moderate function; June 8, fair function; September 12, moderate function. *Biopsies:* February 11, atrophy; March 23, active proliferation; April 6, atrophy; September 11, irregular proliferation; October 4, atrophy.

Result.—Spontaneous period occurred on September 12 for three days, otherwise no change in menses.

A. P., aged 25 years, had secondary amenorrhea for nine and one-half months. There had been loss of libido. *Previous therapy:* Thyroid, and estrone 10,000 I.U. three times a week. *Implant:* Sept. 7, 1940, 55 mg. of estrogen. *Smears:* September 7, fair estrogenic function; September 28, excellent estrogenic function. *Biopsies:* July 24, atrophy; August 28, mild proliferation.

Result.—There was a spontaneous menstrual period on October 18 for four days. She is still under observation. No effect on libido.

DISCUSSION

Group I. Surgical and Irradiation Menopause.—Of the 10 menopause castration cases, 8 patients were relieved of all symptoms one week to ten days following implantation. There was 1 failure in a post-radiation case. One patient was observed only a short period of time and no definite conclusion could be made in this instance. Of the 6 patients kept under observation for a sufficient length of time, it was found that the average symptom-free period was four months. One patient, following radiation therapy, was symptom free for a period of three months. These patients were in a much younger age group than those of the spontaneous menopause. Considering the average dose to be 50 mg. and the average symptom-free period one hundred and twenty days, it would appear clinically that the patients utilized approximately 4,100 I.U. of estrogen per day.

Group II. Spontaneous Menopause.—Twelve patients with spontaneous menopause were treated with pellets, averaging 50 mg. in weight. As in the castration cases, a latent period of one week to ten days elapsed before relief in symptoms was noted by the patients. No abnormal bleeding occurred at any time following the implantation. The duration of the symptom-free period, in those patients observed for a sufficient length of time, averaged five months. This was a longer period than existed in the castration group. Roughly, therefore, from clinical observation alone, we may assume that 50 mg. will last one hundred and fifty days, and the patient absorbs an average amount of 3,000 I.U. per day.

Recently, Corner⁷ determined the rate of secretion of estrogenic hormones by the ovaries of the *Macacus rhesus* monkey in an experimental study. He estimated the rate of secretion tentatively as equivalent to 200 I.U. estrone daily. He multiplied this figure by a factor of 15 to allow for the proportionate weight and calculated the rate of production of estrogenic hormone by the human female as equivalent to 3,000 I.U. of estrone daily. There is a striking similarity of the figures obtained by Corner in the production rate of estrone as compared with our clinical estimate of utilization of the hormone in a group of spontaneous menopause cases.

It is interesting to note that those patients who had previous courses of intramuscular injections were able to compare the two forms of therapy. They stated that although intramuscular injections relieved their flushes, intermittently, they did not have the same continuous feeling of well-being, or energy, as when under therapy by pellet implantation. When questioned as to the type of therapy they preferred, they unanimously chose pellet implantation.

It has been the clinical observation of many workers that small amounts of ovarian hormone injected daily give far better results than large amounts administered once or twice a week. This fact was recently brought out by Smith⁸ in an analysis of 77 cases of estrogen therapy of the climacteric. It has been his practice to give daily intramuscular injections of 2,000 to 5,000 I.U. of estrone for a period of two or three months in moderately severe cases.

It is a well-known fact that only 15 to 20 per cent of climacteric women require intensive substitution therapy. However, these patients will not submit to long-continued intramuscular injections either daily or every other day. In the usual course of events, as soon as the patient feels better after the first few weeks of therapy, she will become negligent, and the treatment then becomes quite sporadic. Obviously, a method which will afford a continuous flow of hormone over a long period of time, following a single treatment, has tremendous appeal to the patient.

Another clinical observation was made in the pruritus vulvae cases associated with menopause. Some of these patients had previously been treated with estrogenic ointment, both for atrophic and hypertrophic vulvitis. They found that when the ointment was discontinued, their symptoms returned rather promptly and they were much more comfortable for a longer period of time under pellet therapy, especially

in cases of atrophic vulvovaginitis, where long-continued therapy caused increased changes in growth and vascularity of the vaginal mucous membrane. Many patients who complained of frigidity and dyspareunia found that these symptoms were definitely relieved.

Group III. Primary and Secondary Amenorrhea.—In 2 cases of secondary amenorrhea, biopsies showed evidence of a moderate proliferation of the endometrium. Vaginal smears showed an increased amount of cornified epithelial cells. An increase was noted in the size of the uterus which had previously shown evidence of hypoplasia. Implantation had no effect whatsoever upon the menstrual cycle. This observation is, perhaps, consonant with the accepted theory of menstrual bleeding as a deprivation effect. In pellet implantation the effect is continuous, and there are no periods of withdrawal at which times bleeding might be expected.

Three patients with primary amenorrhea were treated with implantation of estrogen pellets, averaging 55 mg. in weight, in order to observe the effect of long-continued administration upon the size of the uterus and upon the development of the secondary sex characteristics. The effect upon breast development in these cases was rather striking. Within a period of five to eight weeks, a noticeable increase in the size of the mammary glands and of the nipple area occurred. Lack of breast development was a disturbing factor in the patient's psyche. This was relieved after development took place in a comparatively short period of time.

CONCLUSIONS

1. Estrogen therapy by implantation of 50 mg. pellets is a safe and effective mode of therapy in cases of menopause.
2. Long-continued administration by implantation is more economical to the patient.
3. Pellet implantation is a simple office procedure.
4. No untoward effects were observed in a series of 28 cases.
5. Therapy by pellet implantation for the menopausal syndrome has proved more effective than that obtained by intramuscular injection.
6. In patients with primary amenorrhea, complaining of lack of breast development, satisfactory results have been obtained with pellet implantation.

The pellets used in this study were composed of the finely powdered estrogenic compounds derived from pregnant mares' urine (estrone, equilin, equilenin, and estradiol). The material was compressed in a steel die punch tablet machine without addition of any inert diluent. Material was furnished through the courtesy of Dr. C. F. Longfellow of G. W. Carnrick Co., Newark, N. J.

REFERENCES

- (1) *Deanesly, R., and Parkes, A. S.*: Proc. Roy. Soc. B. 124: 279, 1937. (2) *Idem*: Lancet 2: 606, 1938. (3) *Bishop, P. M.*: Brit. M. J. 1: 939, 1938. (4) *Salmon, U. J., Walter, R. I., and Geist, S. H.*: Science 90: 162, 1939; Proc. Soc. Exper. Biol. & Med. 43: 424, 1940. (5) *MacBryde, C. M., Freedman, H., Loeffel, E., Allen, D.*: Proc. Soc. Exper. Biol. & Med. 43: 212, 1940. (6) *Bennett, H. G., Jr., Biskind, G. B., and Mark, J.*: AM. J. OBST. & GYNEC. 39: 504, 1940. (7) *Corner, G. W.*: Bull. Johns Hopkins Hosp. 67: 407, 1940. (8) *Smith, E. C.*: Surg., Gynec. & Obst. 71: 744, 1940. (9) *Mishell, D. R., Motyloff, L.*: AM. J. OBST. & GYNEC. 39: 796, 1940.